

## PATIENT

Giovanna Solis

## SPECIES

Canine

## BREED

Min. Schnauzer

## SEX

FS

## AGE

13 y

## WEIGHT

16.5 lb

## PRESENTING CLINICAL SIGNS

Recheck degenerative valve disease. Receiving pimobendan 2.5 mg BID.

## ECHOCARDIOGRAPHIC FINDINGS

2D, M-mode, and Doppler study.

There is mild left atrial dilation. The mitral valve leaflets are mildly thickened and exhibit systolic prolapse. A moderate jet of mitral regurgitation is present. There is mild left ventricular dilation. Left ventricular systolic function is hyperdynamic. The aorta and aortic valve are normal. Right atrial and right ventricular dimensions are normal. The tricuspid valve leaflets are mildly thickened, and a mild jet of tricuspid regurgitation is present. The pulmonary artery and pulmonic valve are normal. No shunting lesions are visualized. No heartworms are visualized. No pericardial effusion or cardiac masses are seen.

LA - 32.5 mm  
 LVIDd - 33.8 mm  
 LVIDs - 17.1 mm  
 FS - 49.4%  
 RA - 18.8 mm  
 LVOT - 1.67 m/s  
 RVOT - 1.28 m/s  
 TR - 3.89 m/s

## INTERPRETED BY

Keith Blass, DVM, MS,  
 DACVIM (Cardiology)

## ASSESSMENT/RECOMMENDATIONS

Degenerative mitral (stage B2) and tricuspid (stage B1) valve disease

This examination demonstrates no progression of Giovanna's valvular diseases over the past 7 months. As such, her risk for the development of right-sided congestive heart failure remains low, while her risk for the development of clinical signs of left-sided cardiac dysfunction, such as coughing, exercise intolerance, syncope, and labored breathing, remains only mildly increased.

## IMAGING PERFORMED BY

Kerri Becker

No change in therapy is recommended at this time.

## HOSPITAL NAME

Basking Ridge AH

A recheck echocardiogram is recommended in 9 months. Thoracic radiographs are recommended if Giovanna experiences respiratory clinical signs.

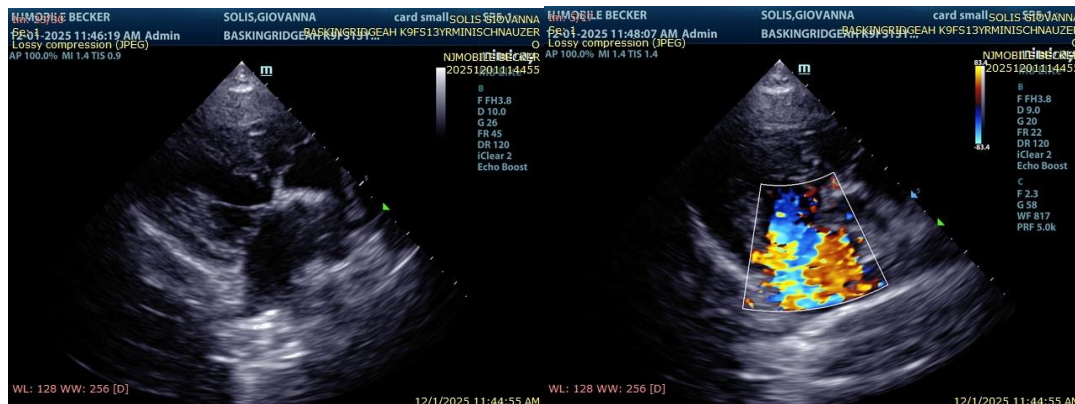
## REFERRING VET

Dr. Blachek

## INVOICE

## DATE

12/1/25





## PATIENT

Giovanna Solis

## SPECIES

Canine

## BREED

Min. Schnauzer

## SEX

FS

## AGE

13 y

## WEIGHT

16.5 lb

## INTERPRETED BY

Keith Blass, DVM, MS,  
DACVIM (Cardiology)

## IMAGING PERFORMED BY

Kerri Becker

## HOSPITAL NAME

Basking Ridge AH

## REFERRING VET

Dr. Blachek

## INVOICE

## DATE

12/1/25

The information and recommendations provided are based on the images presented by the referring veterinarian/sonographer. No evaluation can be communicated regarding pathology that was not visible in the image/video clips provided.

Thank you for this referral. If the clinical or image interpretation does not parallel your findings or if I can be of any further assistance please contact me.

Keith Blass, DVM, MS, DACVIM (Cardiology)

[info@SonoPath.com](mailto:info@SonoPath.com)